

## Combined Ultrasound and Electric Field Stimulation Aids the Healing of Chronic Pressure Ulcers

Jonathan Rosenblum<sup>1\*</sup> and Michael Papamichael<sup>2</sup>

<sup>1</sup>Director, Diabetic Foot Service, Department of Orthopedics, Shaarei Zedek Medical Center, Jerusalem, Israel

<sup>2</sup>Medical Director, Sunharbor Manor, New York, USA

\*Corresponding author: Jonathan Rosenblum, Director, Diabetic Foot Service, Department of Orthopedics, Shaarei Zedek Medical Center, Jerusalem, Israel, Tel: 9722666666; E-mail: [diabfootman@gmail.com](mailto:diabfootman@gmail.com)

Rec date: Jun 24, 2016; Acc date: Jul 05, 2016; Pub date: Jul 09, 2016

Copyright: © 2016 Rosenblum J, et al. This is an open-access article distributed under the terms of the Creative Commons Attribution License, which permits unrestricted use, distribution, and reproduction in any medium, provided the original author and source are credited.

### Abstract

The authors evaluate a novel device that utilizes Combined Ultrasound and Electric Field Stimulation to treat recalcitrant pressure ulcers. The subjects were all residents in our skilled nursing facilities and had the ulcers for more than two months. The evaluation showed that there was a significant increase in healing among patients who had CUSEFS added to their treatment regimen. The results were independent of age of the patients, and size and duration of the wound prior to enrollment. Only location of the wound was found to have an effect on healing rates.

**Keywords:** Ulcers; Aids; Healing; wounds

### Introduction

As the population continues to age, and with more people living longer, the incidence of chronic wounds increases annually [1]. Pressure Ulcer (PU) incidence has been reported as being five to seven times higher in persons older than 80 years compared with persons aged 65 to 70 years [2]. Care for chronic wounds costs about \$10 billion annually [3], and it is predicted to continue to increase annually. It is likely that wound care in adults aged 65 and older accounts for the majority of these costs. Once a PU has developed, it can be extremely difficult to attain full repair. Those who suffer from a PU may be subjected to longer hospital stays, delayed rehabilitation, and a significant loss of independence, which add other burdens to the psychological trauma of injury and reduced quality of life. If a PU is severe, it can lead to further disabilities, need for surgical interventions, and even fatal infections [4].

As early as 50 years ago, Electric Stimulation was documented to enhance healing of various chronic wounds [5,6]. Ultrasound therapy has likewise been reported in the literature as an adjunct therapy in wound care for approximately 50 years [7,8]. The combination of the two modalities as a therapy for wound care has only been reported once in the literature [9]. The effects of these modalities on the skin and underlying tissues, and their effect on wound healing are many and diverse. They include: fibroblast stimulation, modulation of growth factors, regulation of MMP's in the wound bed and many others [10-15].

The authors evaluate a novel device (BRH-A2 from BRH Medical, Ltd) which implements Combined Ultrasound and Electric Field Stimulation (CUSEFS) and its effect on the healing rates of Grade 3 or worse pressure ulcers. This device has shown promise in wound care for other types of chronic wounds, and the authors look to see if there is promise for the treatment of chronic pressure ulcers as well.

### Materials and Methods

IRB approval was attained for the study. Informed consent was given by the subjects and/or a family member. 53 patients having a total of 61 wounds were recruited from five different Skilled Nursing Facilities. Of these, 47 were evaluable for the study. Of the 14 wounds that were not evaluable, 6 hadn't received enough treatments by the end of the study period, and 8 did not have good enough photographic evidence to be evaluated. The patients' ages ranged from 62-89 and the distribution of males and females was representative of the overall patient population in the facilities. 28/47 (59.6%) of the wounds were on males and 19/47 (40.6%) were on females. All patients were receiving aggressive turning schedules as part of their wound care prevention and treatment, and all were on active dietary and nutritional monitoring and control.

The wounds were distributed as follows: 24/47 were sacral ulcers, 12/47 were ischial and 11/47 were on the heels. All wounds were Grade 3 or worse. Treatments included advanced wound care therapy, excluding active biologic matrices or surgical intervention. Wounds were included in the study if they had been present for at least 60 days, and had not improved by at least 20% in the two weeks leading up to active treatment. The only change to their treatment protocol during the study was the addition of Combined Ultrasound and Electric Field Stimulation (CUSEFS) with the BRH-A2 (BRH Medical) twice weekly.

Patients were treated with the CUSEFS according to the following protocol. Wounds were cleansed with an antiseptic solution, and then Electric Field Stimulation (EFS) was applied for 2 minutes. CUSEFS was applied for 20 minutes and the treatment was completed with another 2 minutes of EFS alone. The wounds were then dressed with the wound care products that were being used prior to initiation of the trial. Digital photography was taken before and after every CUSEFS treatment and a physician evaluated the wounds weekly. The photographs were measured by a single evaluator.

The wound measurements were evaluated at 4 weeks, 8 weeks, and the wounds were followed to 20 weeks.

## Results

Table 1 demonstrates the summary results of the study. Overall 40.4% of the wounds closed by 50% of their surface area at 4 weeks, 87.2% by 8 weeks, and 46.8% showed total closure at 20 weeks. These results were independent of gender, age of the patient and duration of

the wound prior to the study. The only factor that showed significance with regard to the outcome was location of the wound. Heal wounds healed significantly quicker than ischial and sacral wounds, and significantly more of the heel wounds achieved total closure at 20 weeks.

	≥50% closure at 4 weeks	≥50% closure at 8 weeks	Total Closure at 20 weeks
Heel Ulcers	7/11 (63.6%)	11/11 (100%)	9/11 (81.8%)
Ischial Ulcers	5/12 (41.7%)	10/12 (83.3%)	4/12 (33.3%)
Sacral Ulcers	7/24 (29.2%)	20/24 (83.3%)	9/24 (37.5%)
Total	19/47 (40.4%)	41/47 (87.2%)	22/47 (46.8%)

**Table 1:** Summary results of the study.

Table 2 demonstrates the percent closure of the wounds that did not achieve total closure by 20 weeks (n=25). Again, the results were independent of age, size and duration of the wounds prior to initiation

of the study, and again, the only factor that showed significance was location of the wounds. Heal wounds healed significantly better than the ischial and sacral wounds.

	≥50% closure at 20 weeks	60% closure at 20 weeks	70% closure	80% closure
Heel Ulcers	2/2 (100%)	2/2 (100%)	2/2 (100%)	2/2 (100%)
Ischial Ulcers	8/8 (100%)	8/8 (100%)	7/8 (87.5%)	5/8 (62.5%)
Sacral Ulcers	15/15 (100%)	15/15 (100%)	14/15 (93.3%)	11/15 (73.3%)
Total	25/25 (100%)	25/25 (100%)	23/25 (92%)	18/25 (72%)

**Table 2:** % closure at 20 weeks of wounds that did not achieve total closure (n=25).

No adverse events were reported during the course of the study. None of the wounds developed infections, and there were no cases that required discontinuation of treatment with CUSEFS.

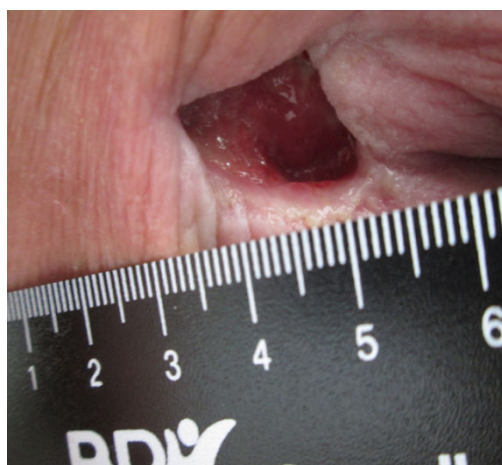Nursing staff reported that quality of life as measured by mobility was improved in all 47 cases. Of the patients who had heel ulcers, all 11 had returned to their pre-ulcerative state of ambulation. Of the patients with the 36 sacral and ischial ulcers all had significantly increased times out of bed and in sitting positions without complaints of pain (Figures 1-3).

## Discussion

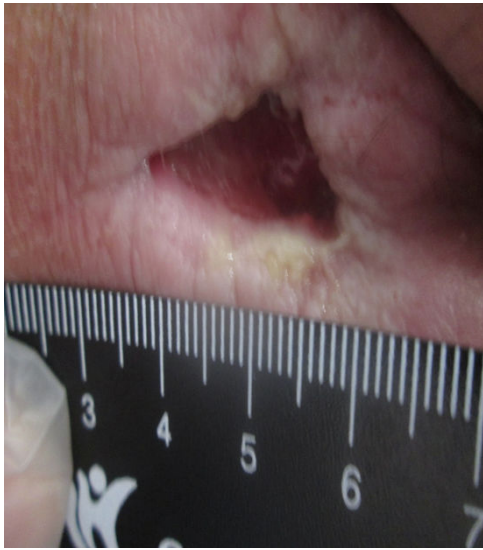
While ultrasound and electric therapy have been utilized therapeutically in wound management for many years, the combination of the two has never been reported. The authors set out to evaluate a new device, the BRH-A2 CUSEFS, which not only combines the two therapies, but is modulated through various frequencies, intensities and waveforms during the course of a treatment session [16].

Avrahami et al evaluated the effect of this device on Diabetic Foot Ulcers and Venous Leg Ulcers and had a different result trajectory [17]. In their study, the wounds had a higher healing rate during the first four weeks but the total closure rates at the studies end were similar to the authors here. The authors hypothesize that the difference in the healing trajectories point towards the underlying nature and etiology of the different wound types. The DFU's and VLU's evaluated by Avrahami have a mostly vascular component and as such the major

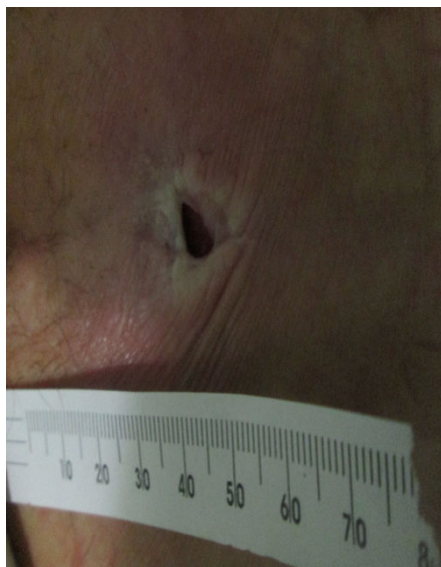physiological activity of the modalities of increasing local blood flow begins immediately and the healing follows quickly. Pressure ulcers are primarily metabolic in nature [18]. Older skin shows considerable atrophy and a prolonged and blunted healing response that can't adapt to the mechanical demands of an injury [19]. There is also heightened inflammation and differences in signal transduction, that result in inferior ECM production [20].



**Figure 1:** Wound at presentation.



**Figure 2:** Wound after 4 weeks of treatment with CUSEFS.



**Figure 3:** Wound after 20 weeks of treatment with CUSEFS.

An interesting result observed in the study was that PU's of the heels healed faster than those on other anatomic locations. The authors would like to suggest that there is a categorical difference between PU's on the heels and elsewhere on the body. Heel ulcers are significantly more akin to vascular ulcers than they are to metabolic ulcers. Whether this is true because of repetitive trauma through years of ambulation or the fact that distal, small vessels are more affected by age needs to be further evaluated.

Both ultrasound and electric field stimulation are known to have positive effects on cellular metabolic rates [9]. This is true when the general health and metabolic function of the patients are within normal limits. Pressure ulcer patients are usually nutritionally and

metabolically challenged as a whole [19]. Thus even with the addition of local stimulation, it takes the body longer to react. However, it appears that once a baseline metabolic rate that can support healing is achieved, healing rates in pressure ulcers increase.

Our results compare favorably with those reported by Korelo et al [9], and with the results utilized for the implementation of therapies for the treatment of pressure ulcers by the EPUAP [21,22].

## Conclusion

BRH-A2 CUSEFS is a good adjunct therapy for recalcitrant pressure ulcers. This is in addition to continued nutritional and nursing support and not as a standalone procedure. While an RCT is certainly recommended, the results of this study strongly suggest a place for CUSEFS in the practitioner's armamentarium.

## References

1. Gould L, Abadir P, Brem H, Carter M, Conner-Kerr T, et al. (2015) Chronic Wound Repair and Healing in Older Adults: Current Status and Future Research. *Wound Repair Regen* 23: 1-13.
2. Margolis DJ, Bilker W, Knauss J, Baumgarten M, Strom BL (2002) The incidence and prevalence of pressure ulcers among elderly patients in general medical practice. *Annals of epidemiology* 12: 321-325.
3. Bickers DR, Lim HW, Margolis D, Weinstock MA, Goodman C, et al. (2006) The burden of skin diseases: 2004 a joint project of the American Academy of Dermatology Association and the Society for Investigative Dermatology. *Journal of the American Academy of Dermatology* 55: 490-500.
4. Cardenas DD, Hoffman JM, Kirshblum S, McKinley W (2004) Etiology and incidence of rehospitalization after traumatic spinal cord injury: a multicenter analysis. *Arch Phys Med Rehabil* 85: 1757-1763.
5. Bogie KM, Reger SI, Levine SP, Sahgal V (2000) Electrical stimulation for pressure sore prevention and wound healing. *Assist Technol* 12: 50-66.
6. Kloth LC, Feedar JA (1988) Acceleration of wound healing with high voltage, monophasic, pulsed current. *Phys Ther* 68: 503-508.
7. Ennis WJ, Lee C, Plummer M, Meneses P (2011) Current status of the use of modalities in wound care: electrical stimulation and ultrasound therapy. *Plast Reconstr Surg* 127: 93S-102S.
8. Taradaj J, Franek A, Brzezinska-Wcislo L, Cierpka L, Dolibog P, et al. (2008) The use of therapeutic ultrasound in venous leg ulcers: a randomized, controlled clinical trial. *Phlebology*. 23: 178-183.
9. Korelo RIG, Kryczyk M, Garcia C, Naliwaiko K, Fernandes LC (2016) Wound healing treatment by high frequency ultrasound, microcurrent, and combined therapy modifies the immune response in rats. *Brazilian Journal of Physical Therapy* 20: 133-141.
10. Furusawa Y, Hassan MA, Zhao QL, Ogawa R, Tabuchi Y, et al. (2014) Effects of therapeutic ultrasound on the nucleus and genomic DNA. *Ultrason Sonochem* 21: 2061-2068.
11. Poltawski L, Watson T (2009) Bioelectricity and microcurrent therapy for tissue healing: a narrative review. *Phys Ther Rev* 14: 104-114
12. Bayat M, Asgari-Moghadam Z, Maroufi M, Rezaie FS, Bayat M, et al. (2006) Experimental wound healing using microamperage electrical stimulation in rabbits. *J Rehabil Res Dev* 43: 219-226.
13. Altomare M, Nascimento AP, Romana-Souza B, Amadeu TP, Monte-Alto-Costa A (2009) Ultrasound accelerates healing of normal wounds but not of ischemic ones. *Wound Repair Regen* 17: 825-831.
14. Cullum N, Al-Kurdi D, Bell-Syer SE (2010) Therapeutic ultrasound for venous leg ulcers. *Cochrane Database Syst Rev* 6: 1180.
15. Polak A, Franek A, Blaszczyk E, Nawrat-Szoltysek A, Taradaj J (2014) A prospective, randomized, controlled, clinical study to evaluate the efficacy of high-frequency ultrasound in the treatment of stage II and stage III pressure ulcers in Geriatric patients. *Ostomy Wound Manage* 60: 16-28.
16. <http://www.brhmedical.com/patient-information>

- 
17. Avrahami R, Rosenblum J, Gazes M, Rosenblum S, Litman L (2015) The Effect of Combined Ultrasound and Electric Field Stimulation on Wound Healing in Chronic Ulcerations. *Wounds* 27: 199-208.
  18. Webb R (2015) How has our view of pressure ulcers changed and what does the future hold? *J Wound Care* 24: 587-588.
  19. Ashcroft GS, Mills SJ, Ashworth JJ (2002) Ageing and wound healing. *Biogerontology* 3: 337-345.
  20. Ashcroft GS, Horan MA, Herrick SE, Tarnuzzer RW, Schultz GS, et al. (1997) Age-related differences in the temporal and spatial regulation of matrix metalloproteinases (MMPs) in normal skin and acute cutaneous wounds of healthy humans. *Cell and tissue research* 290: 581-591.
  21. Korelo RIG, Kryczyk M, Garcia C, Naliwaiko K, Fernandes LC (2016) Wound healing treatment by high frequency ultrasound, microcurrent, and combined therapy modifies the immune response in rats. *Brazilian Journal of Physical Therapy* 20: 133-141.
  22. <http://www.epuap.org/>